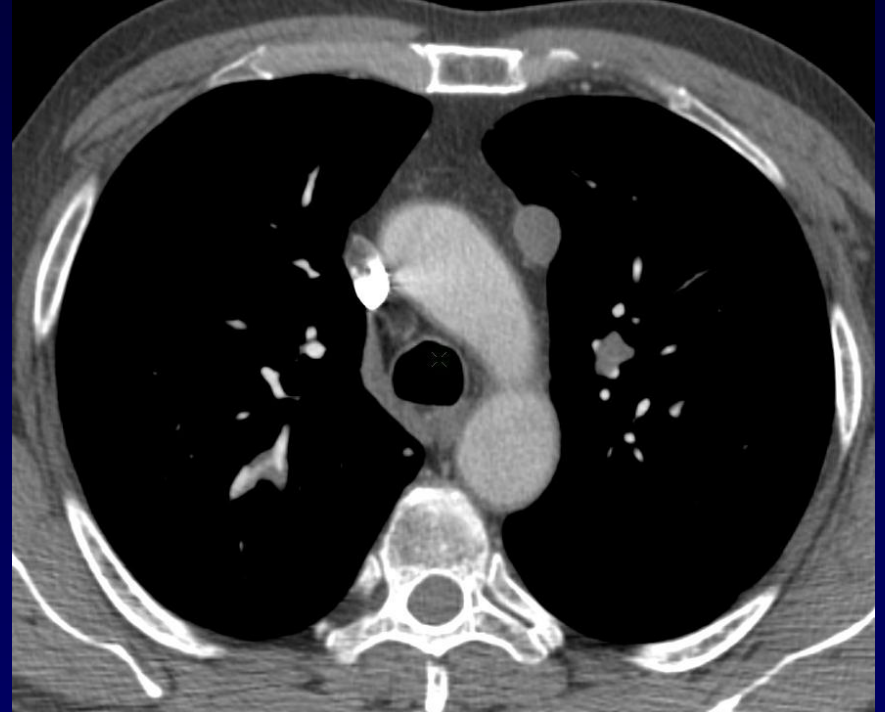
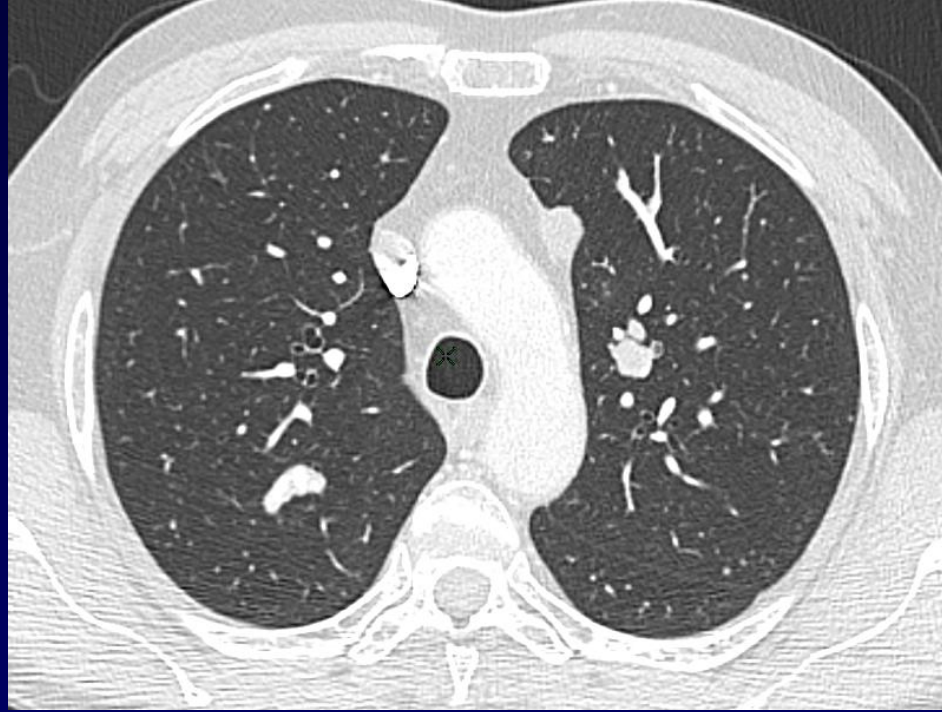


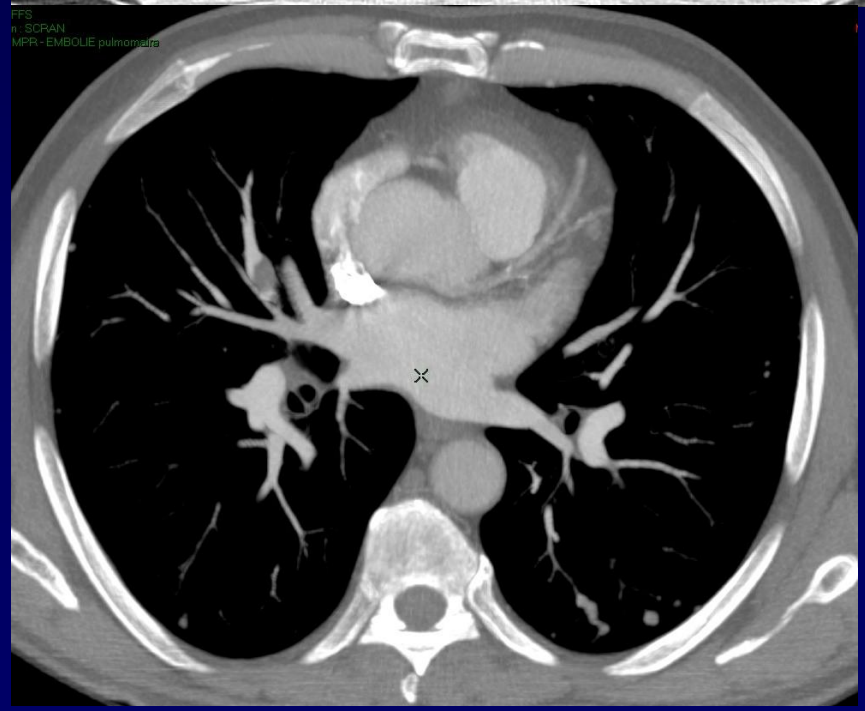
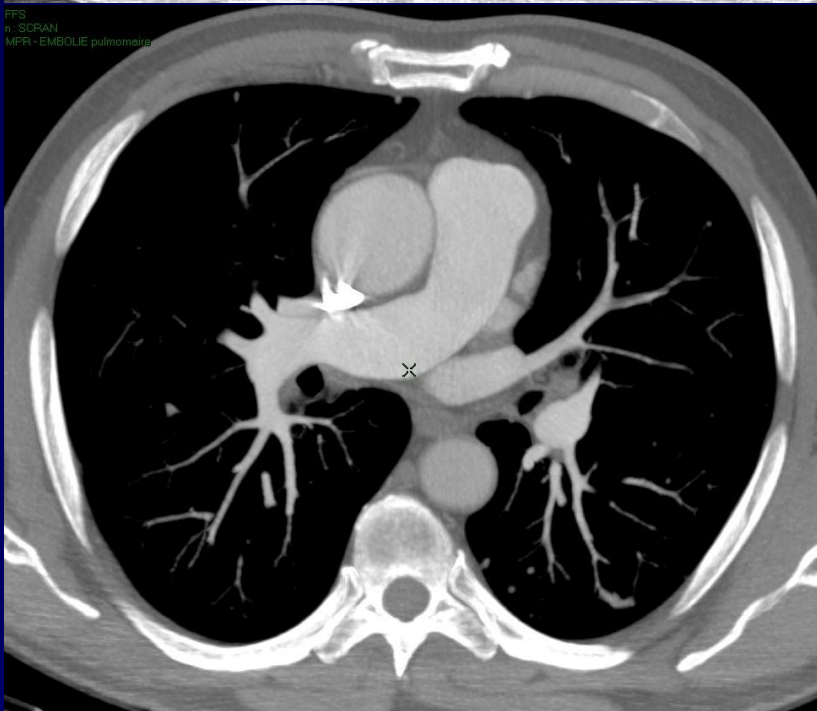
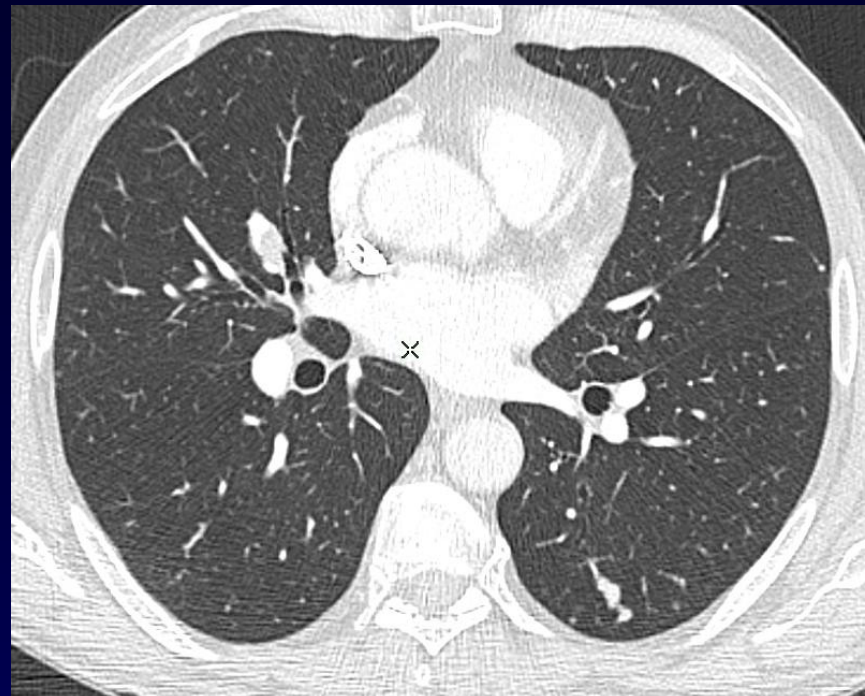
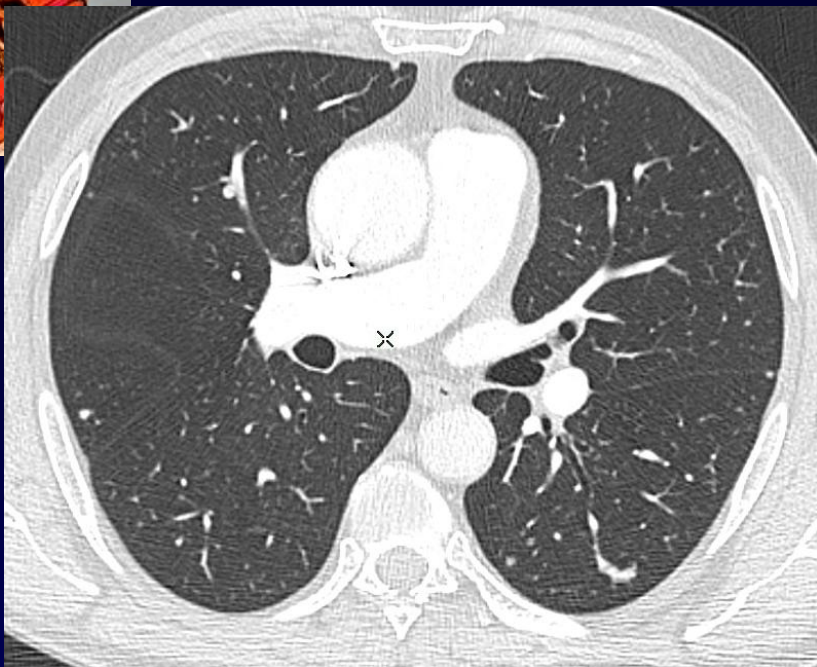
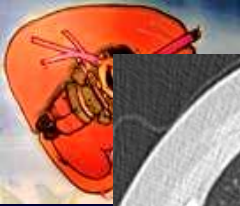

Marie Pierre Debray

Homme de 76 ans

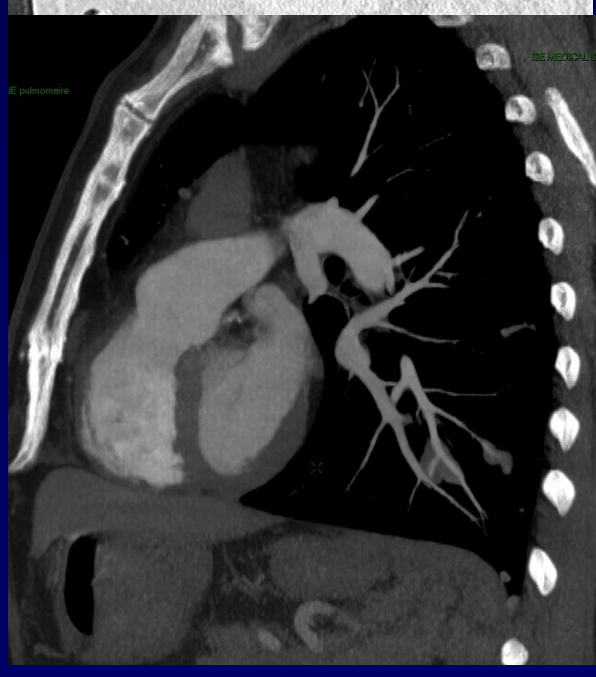
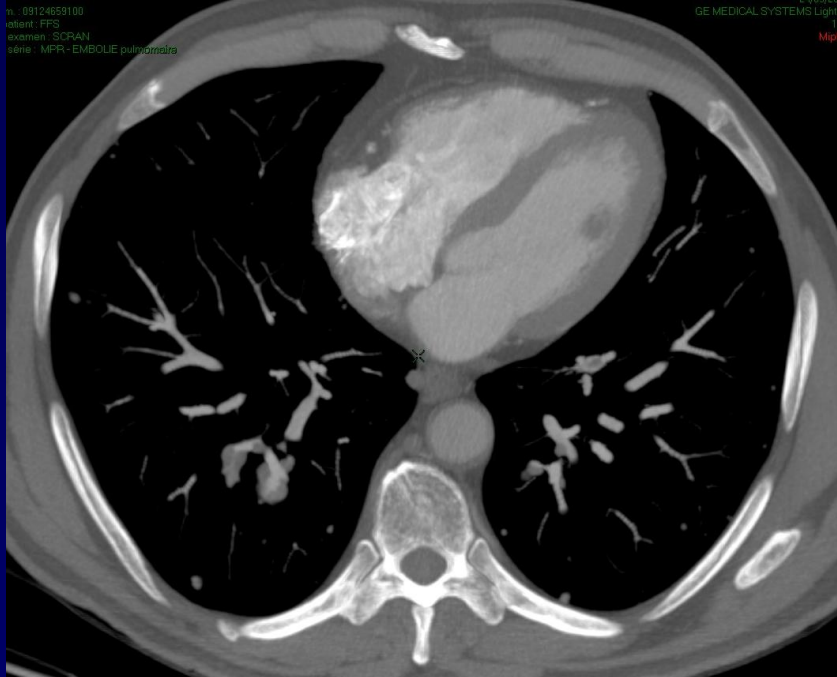
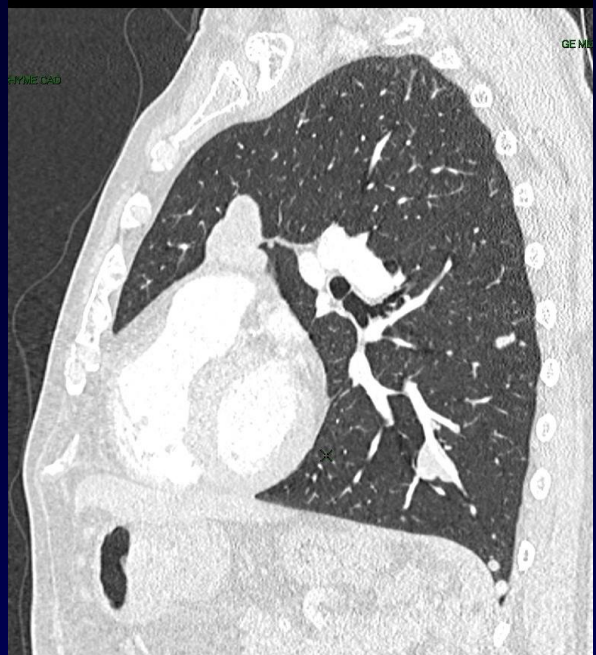
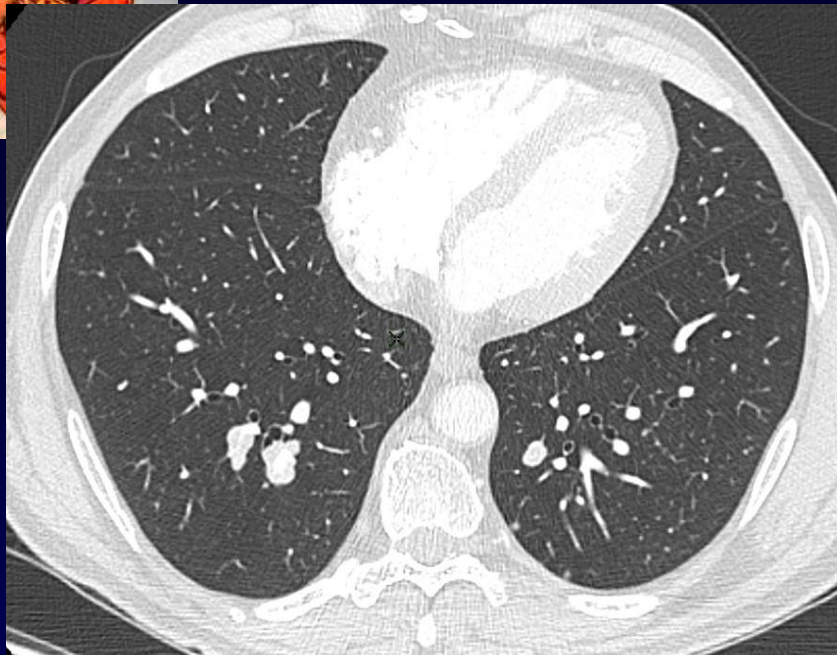
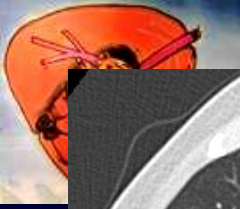
Suivi d'un carcinome à cellules claires rénal opéré





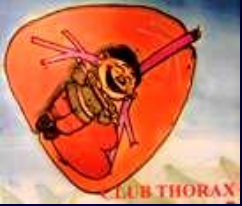FFS
n. SCRAN
MPR - EMBOLIE pulmonaire

FFS
n. SCRAN
MPR - EMBOLIE pulmonaire





Diagnostic ?



Métastases intra-artérielles à extension extravasculaire du cancer rénal